

# Isolated Renal Hydatid Cyst Mimicking Renal Cell Carcinoma: A Diagnostic Dilemma

ANSHU GUPTA, SHIVANI KALHAN, MANISH K SINGHAL, ONIS SINGHAL, VIPLESH KAUR

## ABSTRACT

**Context:** Hydatidosis due to *Echinococcus granulosus* is a parasitic zoonosis with worldwide occurrence. The most common locations are liver and lung. Occasionally, it may mimic intra abdominal tumour.

**Aims:** Hydatid disease of the urinary tract is uncommon, occurring in only 2 to 3% of all cases. This case is presented with the aim of highlighting a giant renal echinococcus cyst, misdiagnosed as renal malignancy on imaging.

**Setting:** The misdiagnosis of renal carcinoma was made in the case of a 65-year-old man.

**Materials and Methods:** The patient presented with colicky pain in right flank with fever, nausea and vomiting. Right kidney

was palpable with leucocytosis and proteinuria.

X ray abdomen revealed ring calcifications in right upper quadrant. Ultrasonography (USG) and computerised tomography (CT) showed a soft tissue mass in right kidney.

Intravenous urography with conventional tomography 15 minutes after contrast demonstrated nil nephrogram in right kidney.

CT findings were suggestive of renal cell carcinoma.

**Conclusions:** Hydatid cyst can attain large dimensions and can easily be misdiagnosed as a tumour. Despite its rarity, hydatid disease should be considered in the differential diagnosis of renal space-occupying lesions.

**Key Words:** Hydatid cyst, renal cell carcinoma, Echinococcosis

## INTRODUCTION

Hydatidosis which is caused by *Echinococcus granulosus* is a parasitic zoonosis which is seen worldwide. The most commonly involved anatomical locations are the liver and the lung. Occasionally, the cyst may mimic an intra-abdominal tumour or it may present with gross ascites [1]. Hydatid disease (HD) of the urinary tract is uncommon, accounting for only 2 to 3% of all the cases [2].

Herein, we are reporting the case of a 65-year-old patient with a giant renal echinococcus cyst, which was misdiagnosed as a renal malignancy on radiology, with the aim of reiterating the consideration of this diagnosis for those who deal with renal space occupying lesions.

## CASE REPORT

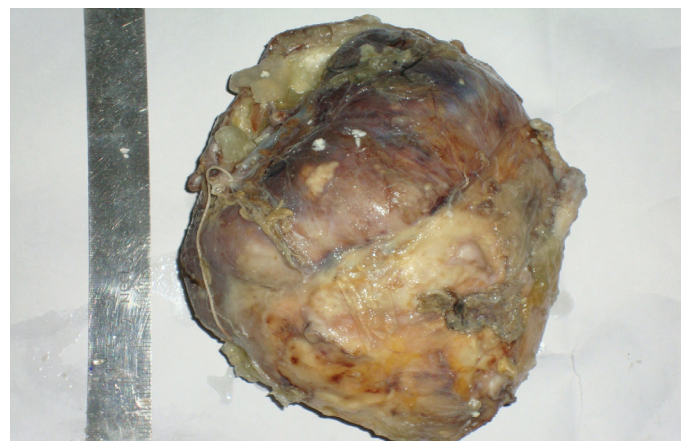
A 65-year-old man was admitted to the emergency ward with colicky pain in the right flank, which radiated to the right, lower quadrant, along with low grade fever of 20 days duration, nausea and vomiting. His past medical history was unremarkable. His clinical examination revealed a palpable right kidney with leucocytosis (11,800 cells per cmm) and proteinuria (++)

No serological tests were performed in this case, as the diagnosis of hydatid cyst was not entertained by the clinicians pre-operatively and as the histopathological examination after nephrectomy was consistent with the diagnosis of a hydatid cyst.

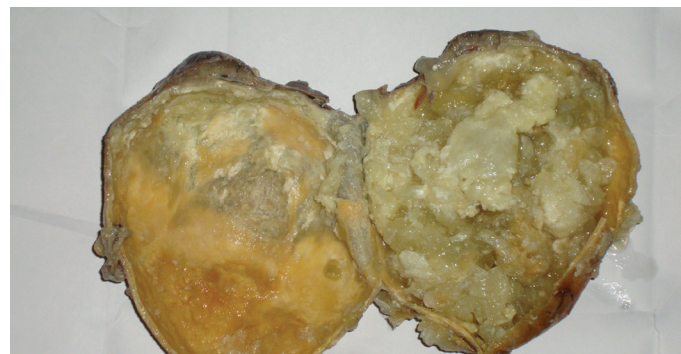Conventional abdominal radiography revealed ring-shaped calcifications in the right upper quadrant. Ultrasonography (USG) showed a soft tissue mass in the right kidney, with multiple hyper-echoic septations.

Intravenous urography with conventional tomography, 15 minutes after contrast, demonstrated normal excretion in the left kidney, but a nil nephrogram in the right kidney.

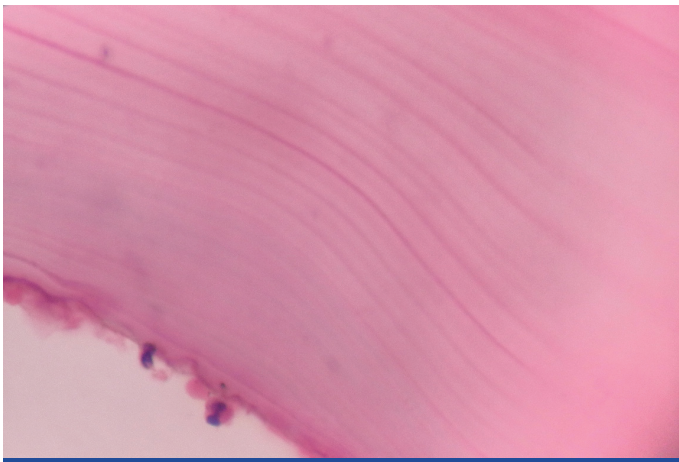
Computed tomography (CT) demonstrated a solid-cystic mass in the right kidney, which measured 16x11x10cm, with a calcified periphery and multiple necrotic areas. The local lymph nodes were enlarged. The renal vein was spared. The CT findings were suggestive of renal cell carcinoma, stage T2N1M0.



**[Table/Fig-1]:** Right nephrectomy specimen



**[Table/Fig-2]:** Right kidney bisected to show renal tissue compressed at upper pole by pseudotumoral hydatid cyst



**[Table/Fig-3]:** Laminated cyst wall (H&E, 400X)

A right sided total nephrectomy with resection of the right 12th rib was done.

The specimen measured 17x14x10cm. The external surface was bosselated. On the cut section, the cortex and the medulla could not be delineated. The kidney was converted into a cyst which was filled with a gel like material, with multiple small daughter cysts which ranged from 0.5x0.5 to 2x2 cm in size. The renal pelvis could not be identified. At one pole, compressed kidney tissue was seen.

Microscopic examination showed that the renal parenchyma was infiltrated by lymphocytes and eosinophils. Focal epithelioid cell granulomas with giant cells were seen.

Sections from the cyst showed a hydatid cyst wall with an outer fibrotic pericyst, a middle acellular, laminated ectocyst and an inner germinal layer (endocyst). Scolices with hooklets were seen in the proteinaceous cyst fluid. Focal areas of calcification were present. There was no evidence of malignancy.

The patient made an uneventful recovery and he was discharged on the 8th postoperative day on albendazole for two months. There was no recurrence till up to nine months of follow up.

## DISCUSSION

Echinococcosis is a zoonosis for which dog is the definitive host. The adult tapeworm resides in the intestine of the dog and produces larvae that cause echinococcosis. The infection occurs when humans are exposed to contaminated faeces. Once ingested, the larvae hatch and they penetrate the wall of the duodenum, and enter the portal circulation. A majority of the tapeworms are entrapped in the liver. Some organisms may proceed to the pulmonary circulation. A small percentage of the larvae may enter the systemic circulation and seed any viscus. After the infection of the visceral organ, vesiculation occurs and a hydatid cyst is formed. The rate of development of a hydatid cyst is very slow. For the cyst to attain a clinically evident size, a long period of time is required.

There are 3 zones in the wall of a hydatid cyst: a peripheral zone of fibroblasts, an intermediate hyalinized layer, and the innermost germinal layer that contains nucleated epithelium. The latter gives rise to brood capsules from which the scolices develop. The brood capsules or the daughter cysts detach and float in the fluid within. The growing cyst causes a mass effect upon the affected organ.

The diagnosis of a hydatid cyst is sometimes difficult. The patient may remain asymptomatic for many years [1]. When the symptoms

appear, pain is the commonest feature. Fever with chills and rigors can occur if the cyst is secondarily infected. Rupture of the cyst is the most common complication and it can be the result of trauma or pressure from the growing cyst [3]. This may result in an anaphylactic shock and in the formation of localized or generalized secondary echinococcosis.

The most common locations are the liver and the lung. Occasionally, the cyst may progressively increase in size, mimicking gross ascites or an intra-abdominal tumour [1]. Involvement of the kidneys is uncommon and the patient can remain asymptomatic for a long period. The patients with kidney involvement may present with haematuria, abdominal discomfort and an abdominal mass. This may mimic genitourinary (GU) tumours which include complex renal cysts and renal cell carcinoma [4]. A renal hydatid disease has no specific signs, except for hydatiduria. The latter is the presence of "grape skin" debris in the urine, when the cyst ruptures into the collecting system. This has been reported in 29% of the cases [5]. Hydatiduria, is a rare cause of renal colic [6]. Because of the risk of a fatal anaphylaxis, partial or total nephrectomy is the preferred treatment [7]. Serologic testing in cases of renal hydatid cyst has proved useful, but it has a sensitivity of only 60%-90% [8].

Radiologic studies help in the diagnosis of renal HD, but they may be inconclusive, and the diagnosis may be made at the time of the cyst removal. The diagnostic accuracy has been greater ever since ultrasonography and immunologic studies have been made available [9]. Ultrasonography (US) is particularly useful for the detection of the cystic membranes, septa, and the hydatid sand. Computed tomography (CT) demonstrates the cyst wall calcification and the cyst infection best [10]. Spherical cysts with a peripheral calcification may be seen on a plain radiograph of the abdomen and these are indicative of HD. A thick, calcified cystic wall suggests the presence of a hydatid cyst. The most pathognomonic finding is the presence of daughter cysts within the larger cyst. The hydatid cyst appears as a unilocular or a multilocular mass on an ultrasonogram or a CT scan. The multilocular appearance indicates the presence of daughter cysts. The CT density of the viable daughter cysts is lower than those of the mother hydatid cysts. The differential density between the mother and daughter hydatid cyst fluid is a useful diagnostic sign [11].

An early diagnosis of a hydatid cyst may be life saving. Potentially lethal complications such as an anaphylactic shock may occur due to perforation of the cyst. Complete elimination of the parasite from the organism and prevention of the recurrence of the disease constitute the ideal treatment for hydatid disease [12].

The treatment options for hydatid cyst of the kidney depend on the stage, localization, size, and the complications in the respective patients and these include medical treatment and operative procedures. The operative methods include conservative and radical procedures along with minimally invasive and laparoscopic methods. The surgical options which include partial or total nephrectomy have been frequently exercised, preferred and reported [7,9,13]. A renal-sparing surgery which involves cystectomy and pericystectomy, is possible in upto 75% of the cases. Nephrectomy must be reserved for destroyed kidneys which result from aged cysts which open into the excretory cavities and are complicated by the renal infection and this has been reported in 25% of the cases. Whether it is conservative or radical, the first surgery which is performed is cystectomy, with the removal of the germinal membrane after a careful evacuation and opening of the cyst, thus making the subsequent steps of the surgery easier [9].

Chemotherapy with antihelmintics of the benzimidazole family, when they are used alone, is of limited efficacy due to the poor accessibility of the cyst to the drug. The outcome is better when the same is used in conjunction with surgery and this aids in preventing a recurrence [4].

In conclusion, we believe that a hydatid cyst can attain large dimensions, sometimes without any symptoms, and that it can easily be misdiagnosed as a tumoural/pseudotumoural mass. Despite its rarity, hydatid disease should be considered in the differential diagnosis of all renal space-occupying lesions [13].

## REFERENCES

- [1] Petrakis IE., Grysolaki E, Paraskakis S, Lagoudis T, Filis D, Chalkiadakis G. Pseudotumoral hydatid cyst: report of a case. *HPB Surg.* 2009; 137956. Epub 2009 Aug23.
- [2] Von Sinner WN, Hellstrom M, Kagevi I, Norlen BJ. Hydatid disease of the urinary tract. *J Urol* 1993; 149:577-580.
- [3] Turgut AT, Altin L, Topçu S, et al. The unusual imaging characteristics of complicated hydatid disease. *European Journal of Radiology* 2007; 63 (1): 84-93.
- [4] Migaleddu V, Conti M, Canalis GC, et al. Imaging of renal hydatid cysts. *AJR Am J Roentgenol* 1997; 169:1339-42.
- [5] Angulo JC, Sanchez-Chapado M, Diego A, Escribano J, Tamayo JC, Martin L. Renal echinococcosis: a clinical study of 34 cases. *J Urol* 1997; 157:787-94.
- [6] Unsal A, Cimentepe E, Dilmen A, Yenidunya S, Saglam R. An unusual cause of renal colic: hydatiduria. *Int J Urol* 2001; 8:319-21.
- [7] Gogus O, Beduk Y, Topukcu Z. Renal hydatid disease. *Br J Urol* 1991; 68:466-69.
- [8] Wein, Kavoussi, Novick, Partin, Peters. *Campbell Walsh Urology.* 9;458-59.
- [9] Zmerli S, Ayed M, Horchani A, Chami I, El Ouakdi M, Ben Slama MR. Hydatid cyst of the kidney: diagnosis and treatment. *World J Surg* 2001; 25:68-74.
- [10] Pedrosa I, Saiz A, Arrazola L, Ferreiros J, Pedrosa CS. Hydatid disease: radiologic and pathologic features and complications. *Radio Graphics* 2000; 20:795-817.
- [11] Vargas-Serrano B, Ferreiro-Arguelles C, Rodriguez-Romero R, Marcos del Rio N. Imaging findings in renal hydatid disease. *Eur Radiol* 1997; 7:548-51.
- [12] King CH. Cestodes (tapeworms). In: Mandell GL, Bennett JE, Dolin R, eds. Principles and practice of infectious disease. 4th ed. New York, NY: *Churchill Livingstone*, 1995;2544-53.
- [13] Afsar H, Yagci F, Aybasti N, Meto S. Hydatid disease of the kidney. *Br J Urol* 1994;73:17-22.

### AUTHOR(S):

1. Dr. Anshu Gupta
2. Dr. Shivani Kalhan
3. Dr. Manish K. Singhal
4. Dr. Onis Singhal
5. Dr. Viplesh Kaur

### PARTICULARS OF CONTRIBUTORS:

1. Associate Professor
2. Professor
3. Assistant Professor
4. Assistant Professor
5. Assistant Professor

### NAME OF DEPARTMENT(S)/INSTITUTION(S) TO WHICH THE WORK IS ATTRIBUTED:

Department of Pathology, Saraswathi Institute of Medical Sciences,  
Hapur, Ghaziabad, U.P., India.

### NAME, ADDRESS, E-MAIL ID OF THE CORRESPONDING AUTHOR:

Dr. Anshu Gupta  
R13/27, Raj Nagar, Ghaziabad, UP, India - 201002.  
Phone: 09999 66 5416  
Email ID: amitanshu75@gmail.com

### FINANCIAL OR OTHER COMPETING INTERESTS:

None.

Date of Submission: **Dec 19, 2011**  
Date of Peer Review: **Mar 17, 2012**  
Date of Acceptance: **Apr 14, 2012**  
Date of Publishing: **Jun 22, 2012**